

Case Report

Maxillary Sinus-Based Giant Cell Bone Tumor

 Erkan Yildiz,¹  Sahin Ulu²

¹Department of Otorhinolaryngology, Afyonkarahisar Suhut State Hospital, Afyonkarahisar, Turkey

²Department of Otorhinolaryngology, Afyonkarahisar Healty Science University Hospital, Afyonkarahisar, Turkey

Abstract

Giant cell tumors are rare benign tumors of the head and neck. The biggest problem in these tumors is high recurrence rates. A 19-year-old patient who presented to our outpatient clinic with a facial swelling was found to have a fully filled mass in the maxillary sinus.

Keywords: Bone tumor, giant cell, maxillary sinus, surgical excision

Cite This Article: Yildiz E. Maxillary Sinus-Based Giant Cell Bone Tumor. EJMI 2019;3(3):248-250.

Giant cell tumors are mostly located in the inner bones. In the 1950s, the lesions in the mandible were called giant cell reparative granulomas.^[1] Although two different diseases were formerly named as giant cell tumors, they have been named as giant cell tumors.^[2]

Giant cell granulomas are benign masses of the head and neck region which are rare and can be located in different localizations. The most common sites are the maxilla, the mandible and the lesser bones and periorbital regions.^[3] It is more common in childhood and adolescence. It is not usually spread and has a benign character, but occasionally it may cause excessive involvement by forming lytic lesions in the bone.^[4,5]

Limited surgery is the basic treatment principle. It should be followed regularly at frequent intervals because of the high likelihood of recurrence. The rate of recurrence ratio is respectively maxilla, mandible and periorbital bone regions.^[6]

In our case, a case of giant cell tumor presenting with right cheek swelling and holding the right maxillary sinus is presented.

Case Report

A 20-year-old female patient was admitted to our outpatient clinic with swelling on the right cheek for 3 months. The patient did not describe nasal bleeding, nasal blow and nasal obstruction. There was no significant feature in the patient's medical history. Physical examination revealed a mild swelling in the right maxillary region, and palpation was not present. Direct nasal endoscopy revealed a mass in the right nasal cavity that completely filled the bottom of the lower turbinate (Fig. 1). There were no pathological findings. In the patient's facial MRI study, heterogeneous hypointense in T1 and T2A sequences starting from the right half of the maxilla to the maxillary sinus and filling the sinus, extending from the medial section of the maxillary sinus to the right half of the nasal cavity and narrowing the posterior segment of the nasal cavity. A mass lesion was observed with irregular lobulated contoured solids (Fig. 2, 3). The patient underwent Caldwell-Luc operation under general anesthesia. It was observed that the periosteal mass completely filled the right maxillary sinus and destroyed the anterior wall of the maxillary sinus, and the mass which

Address for correspondence: Erkan Yildiz, MD. Afyonkarahisar Suhut Devlet Hastanesi, Afyonkarahisar, Turkey

Phone: +90 530 895 04 16 **E-mail:** dr.erkanyildiz@hotmail.com

Submitted Date: February 01, 2019 **Accepted Date:** April 23, 2019 **Available Online Date:** May 13, 2019

©Copyright 2019 by Eurasian Journal of Medicine and Investigation - Available online at www.ejmi.org

OPEN ACCESS This work is licensed under a Creative Commons Attribution-NonCommercial 4.0 International License.



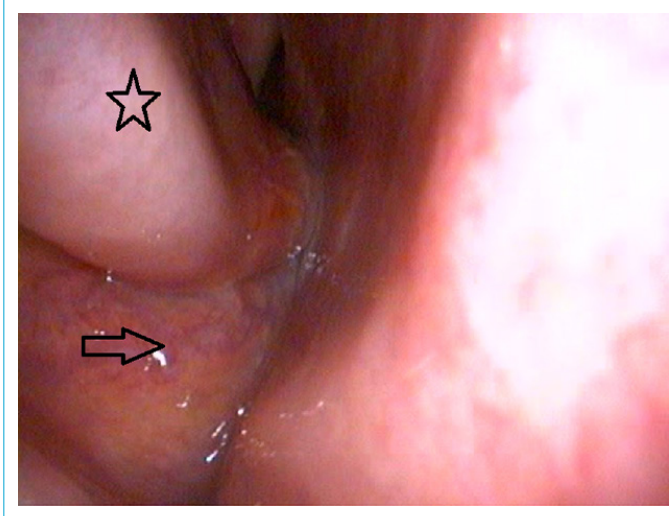


Figure 1. Preoperative Nasal Endoscopic Image.

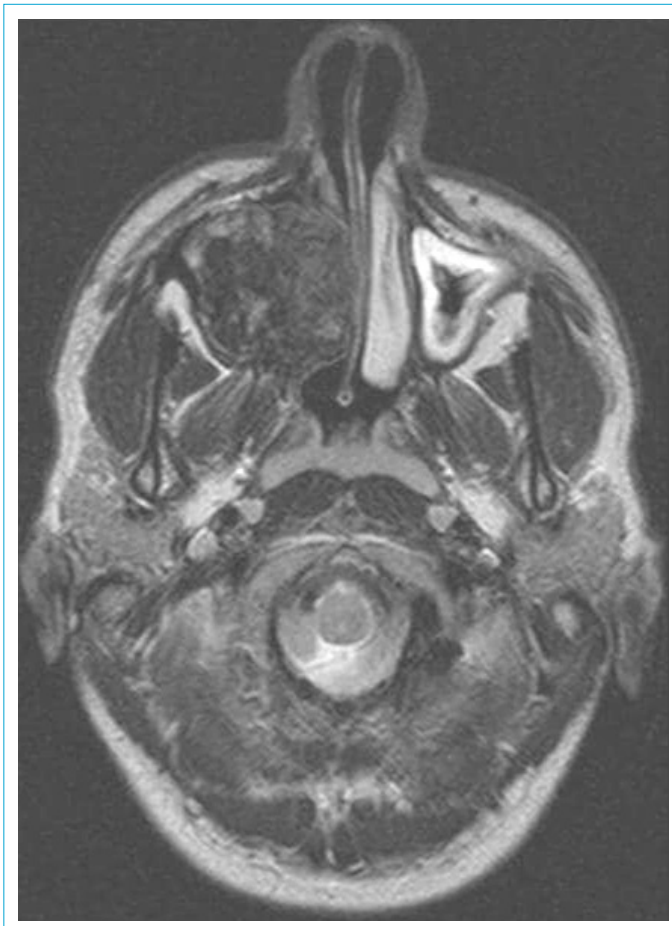


Figure 2. Preoperative Paranasal Sinus MR Image (Axial).

was observed in red, purple, spongy and highly fragile structure was completely removed by curette and lap (Fig. 4). he was repaired. There were no postoperative complications. The material sent to the pathology was reported as 'giant cell bone tumor'. The patient's postoperative para-

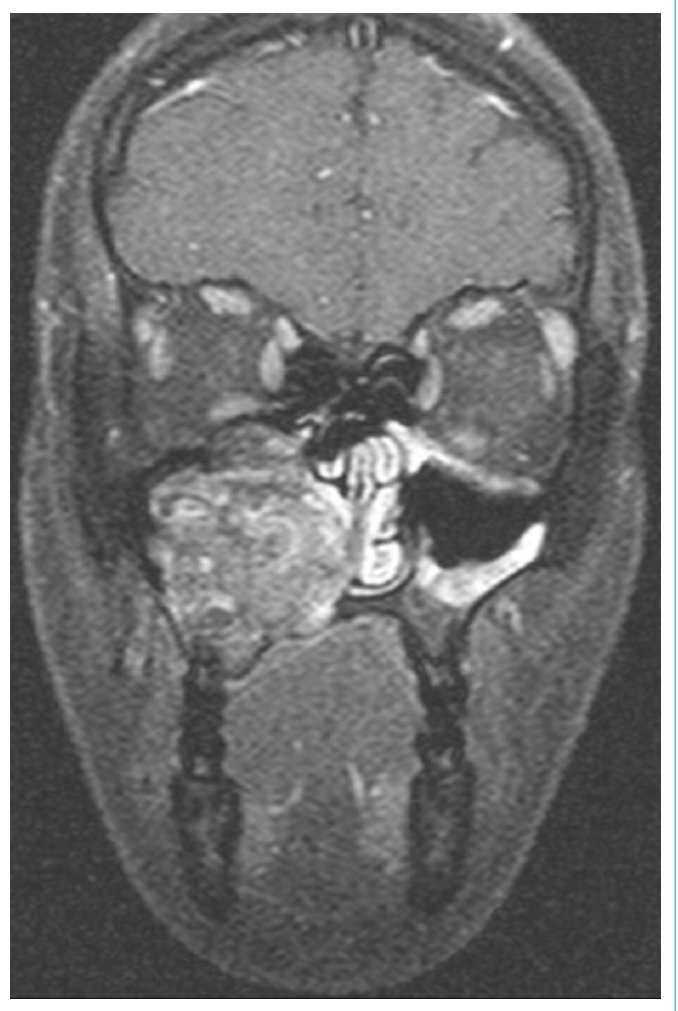

Figure 3. Preoperative Paranasal Sinus MR Image (Coronal).

nasal sinus tomography revealed suspicious lesions on the sinus base at the 8th month postoperatively (Fig. 4). These lesions were followed.

Discussion

Giant cell tumor is a 19-year-old fully described, occasionally limited, occasional, localized mass, forming osteoid halo around the lytic lesion in the bone.^[7,8]

The etiology of these masses is highly controversial. Hemorrhage and inflammatory factors are the factors that are accused of traumatic bone metaphysis. The real cause has not yet been found, but many researchers believe that after they have formed in the body, they have begun to spread out of the same size and mold for a long time.^[9,10] In our case, there was no history of foreign body, operation or trauma to suggest any reparative condition.

The symptoms of giant cell tumor may be due to mass effect. In the literature, symptoms such as dysphagia, numbness, headache, double vision, and nosebleeds were defined.^[11,12]

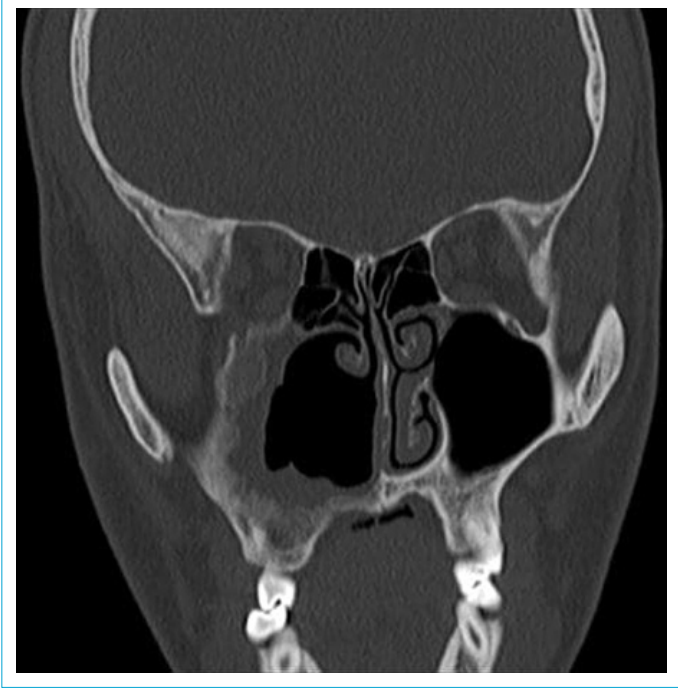


Figure 4. Postoperative Paranasal Sinus CT Image.

Giant cell tumor of head and neck is mostly seen in young women (before 30 years of age) and 1/3 of the lesions are found in 1/3 of the maxilla in the mandible.^[13] In our case, there was a rarely localized maxillary sinus involvement. Our case was female and her age was consistent with the literature.

Giant cell tumors are radiologically small, asymptomatic, well-circumscribed, radiologically open to the middle, swollen like dental cysts; Clinically, the patient may vary from radiographically oriented to light-colored masses.^[14] In our case, a mass lesion with irregular lobulated contoured solids was observed radiologically in the right maxillary sinus.

The main principle in the treatment of giant cell tumor is the complete removal of the mass. Recurrence of the tumor after surgery leads to difficulties in treatment. Because of the younger patient group, limited surgery is the first choice.^[8,15] In our case, we operated the Caldwell-luc incision with the right maxillary sinus and did not need to remove the teeth conservatively.

As a result, giant cell tumor should be kept in mind in the first 20 years of life especially after the trauma without any trauma or trauma.

Disclosures

Peer-review: Externally peer-reviewed.

Conflict of Interest: None declared.

Informed Consent: Written informed consent was obtained from the patient for the publication of the case report and the accompanying images.

Authorship Contributions: Concept – E.Y.; Design – E.Y.; Supervision – S.U.; Materials – E.Y.; Data collection &/or processing – S.U.; Analysis and/or interpretation – E.Y.; Literature search – S.U.; Writing – E.Y.; Critical review – S.U.

References

1. Jaffe HL. Giant cell reparative granuloma, traumatic bone cyst, and fibrous (fibro-osseous) dysplasia of the jawbones. *Oral Surg Oral Med Oral Pathol* 1953;6:159–75. [\[CrossRef\]](#)
2. Abrams B, Shear M. A histologic comparison of the giant cells in central giant cell granuloma and the giant cell tumour of long bone. *J Oral Pathol* 1974;3:217–23. [\[CrossRef\]](#)
3. Morris JM, Lane JI, Witte RJ, Thompson DM. Giant cell reparative granuloma of the nasal cavity. *AJNR Am J Neuroradiol* 2004;25:1263–5.
4. Ciorba A, Altissimi G, Giansanti M. Giant cell granuloma of the maxilla: case report. *Acta Otorhinolaryngologica Ital* 2004;24:26–9.
5. Ficarra G, Kaban LB, Hansen LS. Central giant cell lesions of the mandible and maxilla: a clinicopathologic and cytometric study. *Oral Surg Oral Med Oral Pathol* 1987;64:44–9. [\[CrossRef\]](#)
6. Waldron CA, Shafer WG. The central giant cell reparative granuloma of jaws. An analysis of 38 cases. *Am J Clin Pathol* 1996; 45:437–47. [\[CrossRef\]](#)
7. Avi K, Greg K, Jesus EM. Treatment of giant cell granuloma of the maxilla with intralesional injection of steroids. *Head Neck* 2000;22:822–5. [\[CrossRef\]](#)
8. Quick CA, Anderson R, Stool S. Giant cell tumors of the maxilla in children. *Laryngoscope* 1980;60:781–91. [\[CrossRef\]](#)
9. Greer ro., Rohrer MD, Young SK: Non odontogenic tumours: Clinical evaluation and pathology. Thawley Se. Panje WR. (eds): Comprehensive management of head and neck tumours. WB Saunders Company, Philadelphia, 1987. Volume II. Pp 1534-1536.
10. Güngör A, Poyrazoğlu E, Erol H, Candan H, Özkallı, Yazgın Y. Çenede görülen dev hücreli reparatif granülomlar. *KBB ve Baş Boyun Cerrahisi Dergisi* 1996;4:99–102.
11. Burston HH. Lethal midline granuloma; is it a pathological entity *Jaryngoscope* 69 : I - 43, 1959. [\[CrossRef\]](#)
12. Pearlman SJ, et al; Foreign body granuloma of leh nose. *Laryngoscope* 1923;33:854-6. [\[CrossRef\]](#)
13. Waldron CA, Shafer WG: The central giant cell reparative granuloma of jaws. An analysis of 38 cases. *Am J Clin Pathology* 1966;45:437–47. [\[CrossRef\]](#)
14. Chuong R, Kaban LB, Kozakewich H, Perez AA. Central giant cell lesions of the jaws: A clinicopathologic study. *OralMaxillofacial Surg* 1986;44:708–11. [\[CrossRef\]](#)
15. Stolovitzky JP, Charles AW, Mc Connel FM. Giant cell lesions of the maxilla and paranasal sinuses. *Head Neck* 1994;6:144–8.